

The resistive region of pulmonary microvessels in ovalbumin-sensitised guinea pigs: a quantitative and qualitative histological study

Svitlana Popko^{1*}

^{ID} <https://orcid.org/0000-0002-5533-4556>

Valentina Yevtushenko²

^{ID} <https://orcid.org/0000-0002-6858-6488>

Andriy Kaplaushenko³

^{ID} <https://orcid.org/0000-0003-3704-5539>

Serhiy Tertishniy⁴

^{ID} <http://orcid.org/0000-0003-3856-4234>

¹ Department of Histology,
Cytology and Embryology,
Zaporizhzhia State Medical University,
Zaporizhzhia, Ukraine

² Department of Histology,
Cytology and Embryology,
Zaporizhzhia state medical university,
Zaporizhzhia, Ukraine

³ Department of Physical Colloid Chemistry,
Zaporizhzhia State Medical University,
Zaporizhzhia, Ukraine

⁴ Department of Pathologic Anatomy
and Forensic Medicine,
Zaporizhzhia State Medical University,
Zaporizhzhia, Ukraine

This work aimed to study the morphofunctional changes in the resistive region of the pulmonary microcirculatory bed in ovalbumin-sensitised guinea pigs. Using histological, morphometric, and statistical methods, we studied the lungs of 48 male guinea pigs in conditions of the experimental allergic inflammatory process. To assess the structural and functional state of medium (51–125 µm) and small (25–50 µm) arterioles, the outer and inner diameters, the thickness of the tunica media, and the Kernogan index were determined. The most pronounced changes, such as thickening of their walls and narrowing of the lumen in the late stages of the allergic inflammatory process, consisted in the restructuring of medium arterioles. Compared to control animals, the inner diameter of the medium arterioles decreased three times ($p^{*}/^{**}<0.05$) in experimental group 4; the thickness of the tunica media of medium arterioles increased two times ($p^{*}/^{**}<0.05$) in experimental group 3. These changes are the result of the increasing tone and hypertrophy of the smooth muscles of the tunica media and the decreasing capacity of arterioles as evidenced by a statistically significant increase of the Kernogan index-indicated hypertrophy and the increasing tone of the smooth muscles of the tunica media and decreasing vascular throughput.

Keywords: arteriole, microcirculation, experimental allergic inflammation, lung, ovalbumin, guinea pig

INTRODUCTION

In recent years, chronic allergic respiratory diseases, particularly bronchial asthma, which is a significant medical and social problem (Hrebniak, Fedorchenko, 2019), have been on the increase. One of the insufficiently investigated phenomena in the study of morphological changes in chronic allergic diseases of the respiratory system is the reaction of the elements of the connective tissue in lungs (microvessels, fibers, immunocompetent cells, smooth myocytes) (Denney et al., 2015; Dotsenko, Yatsenko, 2017).

The components of hemomicrocirculation have high plasticity: the ability to rebuild, undergo hyperplasia, or, conversely, to reduce in accordance with changing conditions of organ functioning. The complex and varied processes of the restructuring of the adaptive vascular wall under the influence of various factors of the organism are well known and have been studied in detail (Gojdalo, 2013; Herasymyuk, Vatsyk, 2018; Hnatjuk, Tatarchuk, 2018; Pronina et al., 2018). Several studies have shown that physiological regeneration of the vascular wall occurs in all its layers and is accompanied by the renewal of the cellular composition and fibrous structures (Witzenrath et al., 2006; Herasymyuk, Vatsyk, 2019). The long-standing view considered the vessels and their immediate surroundings as a zone contained cells, which can differentiate in various directions (Lu et al., 2015). In this case it is safe to say that the vascular system is not one of the equivalent components of the connective tissue, which provided only its blood supply and metabolic processes, but it is its central structure, around which various cellular processes occur normally and after exposure to the organ of various factors (Ha et al., 2019; Reichard, Asosingh, 2019).

The data on the reaction of lung microvessels to the action of various endogenous and exogenous factors are contradictory. Cases of plethora and stasis of postcapillary venules and capillaries, accompanied by stromal oedema have been reported (Nebesna, Yeroshenko, 2015; Pronina et al., 2018). Regarding smooth myocytes of the resistive link of the hemo-

microcirculatory channel, some authors demonstrated hypertrophy and dystrophy of myocytes. However, in morphometric studies their bulk density often does not differ from control values, which is associated with severe oedema (Nebesna, Yeroshenko, 2015). Other authors noted a tendency for hypertrophy and increasing functional activity of vascular smooth myocytes, leading to spasm and even obliteration (Zemmouri et al., 2017; Cai et al., 2019). Therefore, nowadays the question of the structural and functional changes and reactivity of various regions of the microvessels of the lungs in allergic inflammation remains open in the majority of aspects. It has necessitated the disclosure of the morphological aspects of this issue. Our study aimed to assess the morphofunctional changes in the resistive region of the pulmonary microcirculatory bed in ovalbumin-sensitised guinea pigs.

MATERIALS AND METHODS

Animals. The object of the experimental study was lungs, removed from 48 sexually mature male guinea pigs weighing 450–600 g, kept in standard conditions of the animal facility of Zaporizhzhia State Medical University. All manipulations were carried out in compliance with the basic principles of working with experimental animals in accordance with the provisions of the European Convention for the Protection of Vertebrate Animals Used for Experimental and Other Scientific Purposes (Strasbourg, 1986), the General Ethical Principles for Animal Experiments adopted by the First National Congress on Bioethics (Kyiv, 2001), the Order of the Ministry of Health of Ukraine No. 281 of 1 November 2000 'On measures to further improve the organisational standards of work with the use of experimental animals', and the Law of Ukraine 'On the protection of animals from cruelty' (21 February 2006).

Selection, dose, and period of treatment. Induction of an allergic inflammation of the airways was carried out by subcutaneous sensitisation and followed by challenging with intranasal inhalation with ovalbumin (OVA)

(Sigma Aldrich, USA). The guinea pigs were actively sensitised by subcutaneous injections of ovalbumin (0.5 mg/mL) with alum (10 mg/mL in saline) as an adjuvant (AlumVax Hydroxide vaccine adjuvant, OZ Biosciences, France) into the interscapular region on days 0, 7, and 14. From days 21 to 28 of the experiment, the guinea pigs were challenged with inhalation of OVA (10 mg/mL in saline) for 15 min via a nebulizer (Little Doctor International, Singapore, LD-211C) coupled to a plastic box.

Experimental design. The animals were divided into six groups. Eight animals from each group were evaluated in our study. The first four groups were animals sensitised and challenged with OVA, withdrawn from the experiment, respectively, on days 23, 30, 36, and 44 after its start; group 5 was a control group, which received injections and was challenged with saline only; group 6 was the intact group. For the purpose of rational presentation of the obtained data and their interpretation, we conditionally distinguish the early (days 23 and 30 of the experiment) and late (days 36 and 44 after the start of the experiment) periods in the development of the allergic inflammatory process in lungs. The animals were sacrificed by an overdose of thiopental anaesthesia (50 mg/kg) according to the established terms (days 23, 30, 36, and 44 of the experiment). Thiopental (sodium thiopental) was obtained from Brovafarma (Brovari, Ukraine), registration certificate AB-01527-01-10 of 31 May 2021.

Tissue processing and histochemical staining. Lungs were removed and fixed immediately in 10% neutral buffered formalin. Formalin fixed and paraffin wax embedded blocks were selected for histological preparation. Histological sections of 5 µm were stained with haematoxylin and eosin (H&E). Masson's trichrome staining was performed to identify the distribution of collagen and reticular fibres and the interrelation between fibrous elements and ground substance in the vascular wall and the pulmonary interstitium.

Quantification and counting of structural elements. A complex of morphometric studies

was carried out on a Carl Zeiss Primo Star microscope using the ZEISS ZEN 2011 software. To assess the structural and functional state of medium (51–125 µm) and small (25–50 µm) arterioles, the outer (d) and inner (d_1) diameters, the thickness of the tunica media (TM) and the Kernogan index (KI) were determined. TM was examined using the formula:

$$TM = (d - d_1) / 2.$$

The morphofunctional indicators of blood vessels are criteria reflecting the morphological state of the circulatory system of internal organs. Particularly, KI of arterioles gives a digital morphofunctional assessment of their functional activity and reflects the throughput of the hemomicrocirculatory bed. It takes two main components of arterioles, TM and d_1 , into account. Therefore, the assessment of the functional state of arterioles was carried out by determining the Kernogan index:

$$KI = (TM / d_1) 100\%.$$

Statistical analysis. The research results were processed by modern statistical analysis methods on a personal computer using the standard software package Microsoft Office 2010 (Microsoft Excel) and STATISTICA® for Windows v6.0 (StatSoft Inc., USA, license 46 No. AXXR712D833214FAN5). For testing the hypothesis about the normal distribution of the studied parameters, we used the Shapiro-Wilk test and the Kolmogorov-Smirnov test of consistency. For testing the hypothesis that two independent samples belong to the same distribution law, we used the Kolmogorov-Smirnov homogeneity criterion. Values represent the mean (M) and standard deviation of the mean ($\pm SD$) from each animal. The statistical significance of intergroup differences according to the obtained data were established using the parametric Student's t -test (p^*) and the nonparametric U-Whitney-Mann test (p^{**}). The obtained indicators were compared between the median and interquartile range Me ($Q_1; Q_3$). The differences

between the compared values at the level of 95% ($p < 0.05$) were considered statistically significant.

RESULTS

The results of the histological analysis demonstrated that the hemomicrocirculatory bed of guinea pig lungs presented a multicomponent system consisting of the following regions: arterioles of medium and small caliber, precapillary arterioles, capillaries, and postcapillary and muscular venules. Smooth myocytes of the tunica media of the arteries and arterioles were well developed. Sometimes they were located intermittently, forming an interception in the precapillaries (a type of sphincters) in the form of the 'beaded string'. We showed

the processes of structural reorganisation of pulmonary microvessels against the background of the development of the experimental ovalbumin-induced allergic inflammation (Figs 1, 2). First of all, the attention is drawn to the decrease in the inner diameter and uneven thickening of walls of medium and small arterioles (Figs 1c, 1d), accompanied by oedema and disorganisation of the fibrous elements of the connective tissue surrounding the vessels (Figs 1b, 2b, 2c, 2d). Simultaneously, vasodilation and pronounced plethora of the capacitive region of microvessels (Fig. 2b), capillarostasis, and numerous perivascular lymphoid nodules are shown (Figs 1b, 1c, 1d). Small arterioles with almost completely obliterated lumen (arterioles of the 'closing' type) were more often observed in experimental groups (Figs 1c, 1d, 2c).

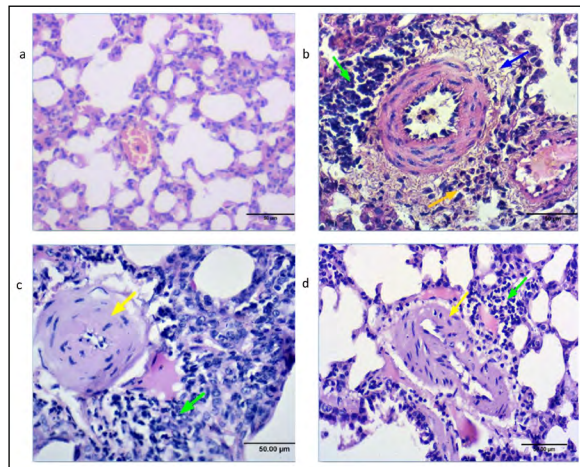


Fig. 1. Microscopic changes in the hemomicrocirculatory bed of guinea pig lungs after sensitisation and challenge with ovalbumin on the days 23 (1b), 30 (1c), and 44 (1d) after the start of the experiment; 1a – control group (H & E, $\times 400$)

Note: spasm and thickening of the arteriole wall (yellow arrows), perivascular lymphoid nodules (green arrows), oedema and disorganisation of the fibrous elements of the ground substance of the pulmonary interstitium (blue arrow), perivascular cluster of eosinophils (orange arrow)

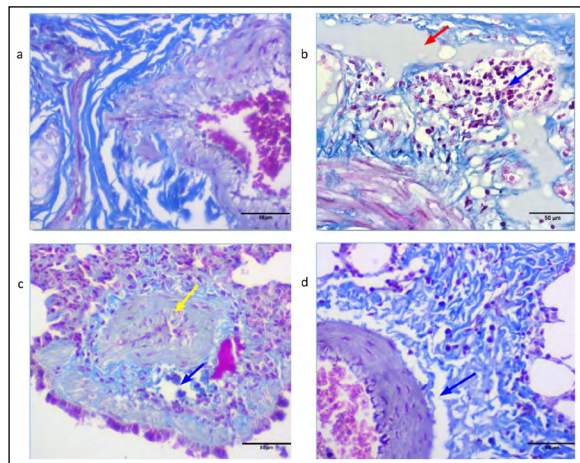


Fig. 2. Microscopic changes in the hemomicrocirculatory bed and the pulmonary interstitium of guinea pig lungs after sensitisation and challenge with ovalbumin on days 30 (2b), 36 (2c), and 44 (2d) after the start of experiment; 2a – control group (Masson's trichrome, $\times 400$)

Note: oedema and disorganization of the fibrous elements of the ground substance of the pulmonary interstitium (blue arrows), spasm and thickening of the arterioles wall (yellow arrows), vasodilation and plethora of venules (red arrow)

Observed at the light-optical level, the histological features of the pulmonary arteriole structure have their own quantitative morphometric display. There was no statistically significant difference between the presented data in the animals of intact and control groups ($p^{*/**} > 0.05$). Consequently, we can conclude that the procedure of OVA-sensitisation and challenge does not itself affect the changes in the morphometric parameters of the arterioles. Nevertheless, we showed morphometric changes in pulmonary arterioles after OVA-sensitisation and challenge in experimental groups (Table 1).

We found that in the early period of the development of the allergic inflammatory process in lungs, the outer diameter (d) of medium arterioles increased by 1.5 times compared to the control group from day 23 after the start of the experiment ($p^{*/**} < 0.05$). The tendency of the widening of the outer diameter of the medium arterioles continued until day 30 of observation; after that, in the late period of the development of the allergic inflammatory process in the lungs, it started narrowing (Table 1).

In the animals of experimental group 2, the outer diameter of the medium arterioles was wider by 1.4 times ($p^{*/**} < 0.05$) than in the control group. On day 36 of observation, the outer diameter of the medium arterioles was by 1.2 times narrower in the animals of experimental group 3, ($p^{*/**} < 0.05$) compared to experimen-

tal groups 1 and 2. On day 44 of observation, the outer diameter of the medium arterioles was almost 1.5 times narrower ($p^{*/**} < 0.05$) in the animals of experimental group 4 compared to experimental group 1 and 1.4 times narrower ($p^{*/**} < 0.05$) in comparison with experimental group 2.

However, we demonstrated a downward tendency in the rate of the inner diameter ($d1$) of the medium arterioles after OVA-sensitisation and challenge. On day 30 of observation in the animals of experimental group 2, the inner diameter of the medium arterioles was 1.2 times narrower ($p^{*/**} < 0.05$) compared to the experimental group 1. The narrowing of the inner diameter of the medium arterioles appeared in the late period of the development of the allergic inflammatory process in lungs (days 36 and 44 after the start of the experiment) in the animals of experimental groups 3 and 4. On day 36 of observation in the animals of experimental group 3, the inner diameter of the medium arterioles was by 1.6 times narrower ($p^{*/**} < 0.05$) compared to the control group, almost twice narrower ($p^{*/**} < 0.05$) in comparison with experimental group 1, and 1.5 times narrower ($p^{*/**} < 0.05$) compared to the experimental group 2. On day 44 of observation, the reduction of the medium arterioles reached the maximum (Table 1). Accordingly, the maximum reduction coefficients in the rate of the inner diameter were observed in experimental group 4:

Table 1. Morphometric parameters of medium arterioles (51–125 μm) in the hemomicrocirculatory bed of guinea pig lungs in normal conditions and after OVA-sensitisation

Group	d , μm	$d1$, μm	TM, μm	KI, %
1 (day 23)	$116.91 \pm 0.98^{*/**}$	39.5 ± 0.90	$38.71 \pm 0.80^{*/**}$	$98.11 \pm 2.75^{*/**}$
2 (day 30)	$116.40 \pm 1.05^{*/**}$	32.51 ± 0.50	$41.95 \pm 0.76^{*/**}$	$129.03 \pm 2.64^{*/**}$
3 (day 36)	95.72 ± 0.74	$21.27 \pm 0.43^{**}$	$42.24 \pm 1.13^{*/**}$	$198.59 \pm 3.87^{*/**}$
4 (day 44)	80.56 ± 1.33	$11.44 \pm 0.07^{*/**}$	$33.94 \pm 0.61^{*/**}$	$296.68 \pm 3.98^{*/**}$
5 (control)	81.68 ± 1.23	34.54 ± 1.33	23.57 ± 0.13	68.24 ± 1.72
6 (intact)	94.50 ± 1.59	42.76 ± 0.99	25.87 ± 0.33	60.50 ± 2.26

Note 1. * – $p < 0.05$ (Student's t -test); ** – $p < 0.05$ (Whitney-Mann U -test) compared to the control group.

Note 2. d – outer diameter; $d1$ – inner diameter; TM – thickness of tunica media; KI – Kernogan index. Values represent the mean \pm SD (standart deviation) in different groups. $n = 8$.

Note 3. The group numbers indicate days after the start of the experiment.

3.0 compared to the control, 3.5 compared to experimental group 1, 2.8 in comparison with experimental group 2, and 2.0 compared to experimental group 3 ($p^{*/**}<0.05$).

We also found a tendency for the elevation of the thickness of the tunica media (TM) of the medium arterioles. TM of the medium arterioles increased by 1.5 times ($p^{*/**} 0.05$) in the early period of the development of the allergic inflammatory process in the lungs in comparison with the control from day 23 after the start of the experiment. This tendency continued to day 30 of observation in animals of experimental group 2, in which TM of the medium arterioles increased by 1.8 times ($p^{*/**}<0.05$) compared to the control group. Moreover, we observed a statistically significant difference between TM of the medium arterioles in the animals of the control group and after OVA-sensitisation in the late period of the development of the allergic inflammatory process in the lungs of the animals of experimental groups 3 and 4. TM of the medium arterioles reached the maximum values on day 36 of observation with the corresponding maximally increased coefficient of 1.9 in comparison with the control. The thickness of TM of the medium arterioles was 1.4 times larger than in the control group ($p^{*/**}<0.05$) in the animals of experimental group 4. The rise of KI in the experimental groups compared to the control reflected the changes in the functional state of the medium arterioles in the lungs

after OVA-sensitisation. In the animals of experimental group 1, KI rose by almost 1.5 times ($p^{*/**}<0.05$) in comparison with the control group. A further elevation of the tone of the medium arterioles was evidenced by the rise of KI in the experimental groups 2, 3, and 4 (by 1.9, 3, and 4.3 times, respectively) compared to the control.

We showed that the outer diameter of the small arterioles widened only in the late period of the development of the allergic inflammatory process in the lungs compared to the control group ($p^{*/**}<0.05$). The tendency of widening of the outer diameter of the small arterioles remained until the end of the experiment (Table 2). On day 36 of observation, the outer diameter of the small arterioles was 1.5 times wider ($p^{*/**}<0.05$) in comparison with the control and experimental group 1 and 1.3 times wider ($p^{*/**}<0.05$) compared to experimental group 2. On day 44 of observation, the outer diameter of the small arterioles was 1.4 times wider compared to the control and experimental group 1 and 1.2 times wider compared to experimental group 2 ($p^{*/**}<0.05$) (Table 2).

The narrowing of the inner diameter in the small arterioles was observed in the late period of the development of the allergic inflammatory process in the lungs in animals of experimental groups 3 and 4 ($p^{*/**}<0.05$). On day 44 of observation, the narrowing of the small arterioles reached its maximum (Table 2).

Table 2. Morphometric parameters of the small arterioles (26–50 μm) in the hemomicrocirculatory bed of guinea pig lungs in normal conditions and after OVA-sensitisation

Group	d , μm	$d1$, μm	TM, μm	KI, %
1 (the 23rd day)	34.60 ± 0.57	19.92 ± 0.28	$7.13 \pm 0.23^{**}$	$35.79 \pm 0.45^{**}$
2 (the 30th day)	38.60 ± 0.81	21.05 ± 0.34	$8.78 \pm 0.43^{**}$	$41.71 \pm 0.48^{**}$
3 (the 36th day)	$52.72 \pm 0.72^{*/**}$	$17.02 \pm 0.32^{**}$	$17.84 \pm 0.45^{*/**}$	$104.82 \pm 1.36^{*/**}$
4 (the 44th day)	$47.12 \pm 0.26^{*/**}$	$13.48 \pm 0.22^{**}$	$16.82 \pm 0.14^{*/**}$	$124.78 \pm 1.52^{*/**}$
5 (control)	34.39 ± 0.41	17.73 ± 0.34	8.38 ± 0.24	50.48 ± 0.48
6 (intact)	39.73 ± 0.28	18.41 ± 0.30	8.54 ± 0.13	46.39 ± 0.54

Note 1. * – $p < 0.05$ (Student's t -test); ** – $p < 0.05$ (Whitney-Mann U -test) compared to the control group.

Note 2. d – outer diameter; $d1$ – inner diameter; TM – thickness of the tunica media; KI – Kernogan index. Values represent the mean \pm SD (standart deviation) in different groups. $n = 8$.

Note 3. The group numbers indicate days after the start of the experiment.

Accordingly, the maximum reduction coefficient in experimental group 4 was 1.3 in comparison with the control group, and 1.6 compared to experimental group 2 ($p^{*/**}<0.05$).

There was a tendency for thickening of the tunica media of the small arterioles. It grew by 2.1 times on day 36 after the start of the experiment compared to the control group. This tendency continued on day 44 of observation in the animals of experimental group 4, in which the thickness of the tunica media of the small arterioles increased twice in comparison with the control group, but shrank compared to the experimental group 3. There was a tendency of dilatation of the small arterioles with absence of a significant increase of thickness of tunica media in contrast to the dynamics of the morphological changes in the wall of the medium arterioles in the early stages of observation in experimental groups 1 and 2 as evidenced by KI reduction by 1.3 times (24%) in experimental group 1 and by 1.13 times (11%) in experimental group 2, in comparison with the KI in the control group. Subsequently, a statistically significant increase in KI in experimental groups 3 and 4 compared to the control (2.2 and 2.7 times, respectively) reflects the functional changes of the small arterioles, such as its increased tone and vasospasm, which reduce its flow ability.

DISCUSSION

The maximum coefficient of the increase in the thickness of the tunica media of the medium arterioles, 1.9, was observed in experimental group 3 in comparison with the control, of the small arterioles, 2, was also in experimental group 3. These changes indicate the compensatory-adaptive processes of microcirculation. OVA-sensitisation and challenge leads to the structural reorganisation of arterioles as a resistive link of the hemomicrocirculatory channel in guinea pig lungs, which has a multidirectional staged nature depending on the diameter of the vessels and the duration of the experiment, and is a manifestation of a violation of the recovery and adaptation processes of hemomicro-

circulation. There is a tendency for vasodilation of small-caliber arterioles in the early period of the development of an allergic inflammation in the guinea pig lungs. Conversely, the reaction of the medium arterioles from the start of the experiment had a unidirectional character and manifested itself in the form of a gradual thickening of the tunica media and narrowing of the lumen due to the growing spasm of smooth muscles. The thickening of the tunica media of the small and medium arterioles and the narrowing of the vascular lumen were demonstrated in the late period of the development of the allergic inflammation in the guinea pig lungs due to the elevation of smooth muscle tone and reduction of the throughput and flow ability, as evidenced by the statistically significant increase in the Kernogan index. With the development of the allergic inflammation in guinea pig lungs, more significant structural and functional changes were observed in the medium arterioles in experimental groups 3 and 4. Our findings are consistent with the findings from earlier studies (Zemmouri et al., 2017; Cai et al., 2019). The most significant contraction of the inner diameter of microvessels, by three times in comparison with the control, was noted in experimental group 4. Considering that the last inhalation took place on day 28 after the start of the experiment, the fact of the narrowing of the inner diameter of medium and small arterioles on days 36 and 44 may indicate the activity of the process of the allergic inflammation in the absence of the action of the allergen, manifested by vasoconstriction of the resistive region of the hemomicrocirculatory bed with the participation of smooth myocytes in guinea pig lungs. In agreement with previous studies (McDonald, 2001; Rydell-Törmänen et al., 2005; Rydell-Törmänen et al., 2008), morphometric changes in the presented data indicate that the development of the ovalbumin-induced allergic inflammatory process in the lungs takes place with the participation of the vascular component of the pulmonary connective tissue. What is more, the duration of its course is not limited by the direct effect of the allergen but also continues after the end of

its action. It may become the basis for the subsequent development of pulmonary hypertension.

CONCLUSIONS

There is a tendency for vasodilation of the small arterioles in the early period of the development of an allergic inflammation in the lungs of guinea pigs. From the start of the experiment, the reaction of the medium arterioles had a unidirectional character and was manifested in the gradual thickening of the tunica media and the narrowing of the lumen due to an increasing spasm of smooth muscles. In the late period of the development of the allergic inflammation in the lungs of guinea pigs, the thickening of the tunica media of small and medium arterioles and the narrowing of the lumen, a statistically significant increase in the Kernogan index indicated hypertrophy and increasing tone of the smooth muscles of the tunica media and decreasing vascular throughput.

CONFLICTS OF INTEREST

The authors declare no conflict of interest in this paper.

ACKNOWLEDGEMENTS

This study is part of the research project of Zaporizhzhia State Medical University 'Immunomorphological characteristics of internal organs under the influence of endo- and exogenous factors on the body' state registration No. 0118U004250, Ukraine.

Received 12 December 2021

Accepted 7 February 2022

References

- Cai Z, Liu J, Bian H, Cai J. Albiflorin alleviates ovalbumin (OVA)-induced pulmonary inflammation in asthmatic mice. *Am J Transl Res.* 2019; 11: 7300–9.
- Denney L, Byrne Adam J, Shea Thomas J, Buckley James S, Pease James E, Herledan Gaelle MF, et al. Pulmonary epithelial cell-derived cytokine TGF- β 1 is a critical cofactor for enhanced innate lymphoid cell function. *Immunity.* 2015; 43: 945–58.
- Dotsenko SYa, Yatsenko OV. [Elastic properties of pulmonary artery in chronic obstructive pulmonary disease.] *Zaporozhye Medical Journal.* 2017; 19: 26–9. Ukrainian.
- Gojdalo TR. [Morphometric characteristics of the alteration of pulmonary and bronchial arteries in the dynamic of experimental modeling of an acute intestinal obstruction.] *Hospital Surgery. Journal named after L. Ya. Kovalchuk.* 2013; 3: 41–5. Ukrainian.
- Ha EH, Choi J-P, Kwon H-S, Park HJ, Lah SJ, Moon K-A, et al. Endothelial Sox17 promotes allergic airway inflammation. *J Allergy Clin Immunol.* 2019; 144: 561–73.e6.
- Herasymiuk IE, Vatsyk MO. [Features of reorganization of blood vessels of lungs of rats at various degrees of total dehydration]. *Morphologia.* 2018; 12: 44–50. Ukrainian.
- Herasymiuk IE, Vatsyk MO. Features of remodeling of blood vessels of rat lungs in applying different methods of fluid resuscitation after general dehydration. *Bull Problems Bio Med.* 2019; 1: 272–6.
- Hnatjuk MS, Tatarchuk LV. Morphometric analysis remodeling vessels hemomicrocirculatory bed of jejunum at resections of liver. *Reports Morphol.* 2018; 24: 16–20.
- Hrebniak MP, Fedorchenko RA. Influence of industrial atmospheric pollution on the development of pathology of respiratory organs. *Pathologia.* 2019; 16: 81–6.
- Lambrecht BN, Hammad H. The immunology of asthma. *Nature Immunology.* 2014; 16: 45–56.
- Lu S, Li H, Gao R, Gao X, Xu F, Wang Q, et al. IL-17A, But Not IL-17F, Is Indispensable for Airway Vascular Remodeling Induced by Exaggerated Th17 Cell Responses in Prolonged Ovalbumin-Challenged Mice. *J Immunol.* 2015; 194: 3557–66.
- McDonald DM. Angiogenesis and Remodeling of Airway Vasculature in Chronic Inflammation. *Am J Respir Crit Care Med.* 2001; 164: 39–45.
- Nebesna ZM, Yeroshenko GA. [Histological and histochemical changes of the lungs after experimental thermal trauma]. *World of Medicine and Biology.* 2015; 2: 141–5. Ukrainian.
- Popko SS, Evtushenko VM, Syrtsov VK. Influence of pulmonary neuroendocrine cells on lung homeostasis. *Zaporozhye Medical Journal.* 2020; 22: 568–75.
- Pronina OM, Koptev MM, Bilash SM, Yeroshenko GA. Response of hemomicrocirculatory bed of internal organs on various external factors exposure based on the morphological research data. *World of Medicine and Biology.* 2018; 1: 153–7.
- Reichard A, Asosingh K. Endothelial cells in asthma. In Pareira C. (ed.), *Asthma – Biological Evidences*, London: IntechOpen; 2019.
- Rose CE, Lannigan JA, Kim P, Lee JJ, Fu SM, Sung SJ. Murine lung eosinophil activation and chemokine production in allergic airway inflammation. *Cell Mol Immunol.* 2010; 7: 361–74.
- Rydell-Törmänen K, Uller L, Erjefält JS. Remodeling of extra-bronchial lung vasculature following allergic airway inflammation. *Respir Res.* 2008; 9: 18.
- Rydell-Törmänen KR, Uller L, Persson CGA, Erjefält JS. Allergen Exposure of Mouse Airways Evokes Remodeling of both Bronchi and Large Pulmonary Vessels. *Am J Respir Crit Care Med.* 2005; 171: 19–25.
- Witzenrath M, Ahrens B, Kube SM, Hocke AC, Rosseau S, Hamelmann E, Suttorp N, Schütte H. Allergic lung inflammation induces pulmonary vascular hyperresponsiveness. *Eur Respir J.* 2006; 28: 370–7.
- Zemmouri H, Sekiou O, Ammar S, El Feki A, Bouaziz M, Messarah M, Boumendjel A. Urtica dioica attenuates ovalbumin-induced inflammation and lipid peroxidation of lung tissues in rat asthma model. *Pharm Biol.* 2017; 55: 1561–8.

Svitlana Popko, Valentina Yevtushenko, Andriy Kaplaushenko, Serhiy Tertishniy

OVALBUMINUI ĮJAUTRINTŲ JŪRŲ KIAULYČIŲ PLAUCIŲ MIKROKRAUJAGYSLIŲ REZISTENCINĖ SRITIS: KIEKYBINĖ IR KOKYBINĖ HISTOLOGINĖ ANALIZĖ

Santrauka

Šio darbo tikslas buvo ištirti ovalbuminui įjautrintų jūrų kiaulyčių plaučių mikrocirkuliacijos vagos rezistencinės jungties morfofunkcinius pokyčius. Ištyrėme 48 jūrų kiaulyčių patinų plaučius histologiniais, morfometriniais ir statistiniais metodais eksperimentinio alerginio uždegiminio proceso sąlygomis. Siekiant įvertinti vidutinių (51–125 μ m) ir mažų (25–50 μ m) arteriolių struktūrinę ir funkcinę būklę, nustatytas išorinis ir vidinis skersmuo, tunikos terpės storis ir Kernogano indeksas. Labiausiai pakito vidutinės arteriolės: užfiksuotas jų sienelių sustorėjimas ir spindžio susiaurėjimas vėlyvoje alerginio uždegiminio proceso stadijose. Lyginant su kontroliniais gyvūnais, ketvirtos eksperimentinės grupės vidutinių arteriolių vidinis skersmuo sumažėjo 3 kartus ($p^{*/**} < 0,05$), o trečios eksperimentinės grupės vidutinių arteriolių tunikos terpės storis padidėjo 2 kartus ($p^{*/**} < 0,05$). Statistiškai reikšmingai padidėjęs Kernogano indeksas rodo, kad šiuos pokyčius lemia lygiųjų raumenų tunikos terpės hipertrofija ir didesnis tonusas bei mažėjantis kraujagyslių pralaidumas.

Raktažodžiai: arteriolė, mikrocirkuliacija, eksperimentinis alerginis uždegimas, plaučiai, ovalbuminas, jūrų kiaulytė